

Plain and drug loaded polyphosphazene membranes and microspheres in the treatment of rabbit bone defects

P. PASSI^{1*}, A. ZADRO¹, F. MARSILIO², S. LORA³, P. CALICETI², F. M. VERONESE^{2*}

¹Dental School, Department of Dental Materials, University of Padua, Italy

²Department of Pharmaceutical Sciences (CNR Center for Drugs and Biological Products), University of Padua, Italy

³Istituto di Fotonica e Radiazioni d'Alta Energia del CNR, Legnaro, Padua, Italy

E-mail: piepas@tin.it

The healing of periodontal surgical defects was studied in rabbits, using polyphosphazenes (POP) membranes and microspheres, both plain or drug-enriched.

POP polymers having amino acid ester as backbone substituents, are used since they resorb and undergo hydrolytic degradation to ammonia, phosphate and amino acids.

Fourteen animals were operated in tibia, and other fourteen at angle of the mandible, that was reached by extraoral access. Bone defects were performed in tibiae, and covered either with POP or with poly-tetrafluoroethylene (PTFE) membranes, while other rabbits served as controls. The animals were sacrificed after one and two months, and the tibiae taken and processed for optical microscopy.

Similar surgical defects were made in mandible, and POP membranes were placed over the breaches, some of which were filled with POP microspheres, both alone or mixed with granular hydroxyapatite. For comparison, two rabbits were treated with PTFE membranes, while other two served as controls. The animals operated at the mandible were all sacrificed after one month, and the operated bones taken and processed for histology.

It was found that POP membranes were very effective in promoting the healing in tibiae, while less satisfactory results were found in the animals treated with PTFE membranes and in controls. In mandible, the healing occurred without a clear relationship with the grafted microgranular material or the membrane, since repairing bone was found also in controls. In any case, both POP membranes and microspheres showed excellent biocompatibility, as no inflammatory cells or macrophages were found in the surrounding tissue. This property was completely independent from the presence of drug, since the matrix-entrapped drugs, released in the tissue, did not hamper the bone healing. It was also found that POP, by itself, has a positive effect in stimulating the bone repair.

© 2000 Kluwer Academic Publishers

1. Introduction

The repair of periodontal defects with the growth of newly formed bone, periodontal ligament and cementum was difficult task, generally with poor results, until the discovering of the so-called guided tissue regeneration (GTR). In this method, natural or synthetic polymeric membranes are utilised, with the aim to isolate the deep periodontum from the soft gingival tissues [1]. Semi-permeable, non resorbable filter membranes were initially employed for this purpose. These were made

of polytetrafluoroethylene (PTFE) or other synthetic organic materials, such as polycarbonate, and gave satisfactory results in experimental trials in animals and in humans [2]. The introduction of expanded polytetrafluoroethylene (e-PTFE) improved the mechanical characteristics of such non-resorbable membranes [3,4]. Experimental trials in monkeys indicate that e-PTFE barriers may lead to the formation of a new periodontal tissue, which contains cells and macromolecules associated with bone and cementum [5].

PTFE and e-PTFE although stiff, can be easily modeled and fitted to the shape required for the surgical site. However such non-resorbable membranes present some disadvantages: they need to be removed with a second surgery after some weeks, and may become

*Authors to whom correspondence should be addressed Prof. Piero Passi, Via Zabarella, 64–35121 Padova- Italy Prof. Francesco Veronese, Dipartimento di Scienze Farmaceutiche Via Marzolo 5–35131 Padova. E-mail: veronese@pdfar3.dsfarm.unipd.it

exposed to the oral environment in a high percentage of cases, about 40%, due to the risk of bacterial plaque accumulation and subsequent infection with poor clinical results [6, 7]. These drawbacks prompted the production of resorbable membranes that do not need removal and also appeared less susceptible to infection if in contact with the oral environment [8–10]. Some of these barriers are of natural materials as collagen or synthetic ones as those made of polylactic (PLLA). These were still visible, swelled and folded, with initial resorption, probably induced by hydrolysis, because no multinucleated phagocytic cells were found. This behavior was reported in particular with polyglycolic-co-lactic acid (PGLA) and with co-polymers PLLA-citric acid ester [11, 13]. Also polyglycolic acid (PGA), non-permeable and resorbable barriers, have been later introduced, which appeared to give more satisfactory results [14]. Polycaprolactone (PCL) and the co-polymers hydroxybutyrate-hydroxyvalerate (PHB-HV) were tested with interesting results in animals [15] as well as poly(ethylene glycol)-poly(butylene terephthalate) (Polyactive™). This last polymer was investigated also for abdominal surgery, in preventing intraperitoneal adhesion [16].

Bioabsorbable membranes seem to be as effective in periodontal therapy as the non-resorbable ones; the integration with the newly-formed connective tissue that they may provide, seems to be a helpful action in preventing bacterial plaque contamination. [17].

Beneficial effects were reported in the treatment of human periodontal furcation lesions, with the use of a partially resorbable synthetic polymer, acting both as bone substitute and barrier [18]; however, these preliminary results have yet to be confirmed.

Other membranes of biologic origin were tested, as collagen barriers [19] or animal laminar bone membranes [20], that showed good clinical results in the treatment of periodontal lesions in humans. However, the risk of introducing some pathologic agent, such as viruses or prions, cannot be totally excluded at this moment, and may suggest caution in the widespread uses of these devices.

Besides this hypothetical risk related to the barriers obtained from animals, especially bovines, the absorbable membranes are not devoid of other disadvantages. Collagen and other biological devices as dura mater can evoke immune response and inflammation [21]. Soft tissue inflammation with gingival recession and exposure of the membrane, are other common complications, owing to the resorption process, mostly due to phagocytosis [22–24].

Furthermore, a problem of many degradable membranes is an insufficient duration to guarantee a valid barrier effect [10]. For all of these reasons a satisfactory membrane for GTR has not been produced until today. In this context of research this article deals with a new type of degradable device, made of polyphosphazene (POP), which, in our opinion, may offer special advantages:

1. A resorption time that depends on the thickness and/or composition.
2. Dissolution by hydrolysis characterized by a very low or no phagocytosis, with concomitant limited risk of inflammation.

3. A stiff but modellable structure.

4. Possibility to entrap inside the membrane antibiotics and/or anti-inflammatory drugs for a slow release into the surrounding tissue by diffusion and/or dissolution of the membrane.

Moreover, this polymer allows to manufacture drug-releasing microspheres or other devices also that, placed in surgical sites, may enhance the therapeutic effect. In this study, we have utilized two polyphosphazenes obtained from polydichlorophosphazene by substitution of chloride atoms by alanine ethyl esters or phenylalanine ethyl ester and imidazole.

2. Material and methods

2.1. Chemistry of the polymer and preparation of membranes or drug-releasing microspheres

Two polyphosphazenes were synthesized: Polymer I with alanine ethyl ester imidazole as polyphosphazene substituents at a molar ratio of 80/20, and polymer II with phenylalanine ethyl ester imidazole as polyphosphazene substituents at a molar ratio of 79/21. The different composition gives rise to products suitable for the preparation of different matrices, the first to obtain membranes and the second for microsphere preparation. The polymer synthesis and its physico-chemical properties were extensively described elsewhere as well as the microcapsule and membrane formation [25–28]. In short, drug enriched membranes were obtained by dissolution of 300 mg of POP I and 15 mg of naproxen, or 15 mg of trimethoprim and succinylsulphathiazole in 1.4 ml of a mixture of 50:50 methylene chloride ethanol. The resulting solutions were poured into teflon caps, 2.8 cm of diameter, and kept at 4 °C at atmospheric pressure for 60 h to evaporate the solvent. The membranes, removed and dried under high vacuum for 24 h, were 1 mm thick. Membranes without drugs were obtained by direct dissolution of 300 mg of POP I in 1.4 ml of methylene chloride and following the same steps as above.

In turn microspheres, enriched by succinylsulphathiazole or naproxen, were obtained dissolving 22 mg of drug and 150 mg of polymer II in 1.2 ml of a 50:50 mixture of methylene chloride and ethanol. The solution was injected under stirring in 200 ml of acetate buffer pH 4.5 containing 5 ml of Tween 80 under stirring and the stirring was maintained for 5 more minutes, while the vacuum was applied to remove the solvent. The microspheres (30–80 µm of diameter) were recovered by centrifugation, washed by water and dried by lyophilization. The operations for both membranes and microspheres formation were carried out under sterile conditions to prevent bacterial contamination.

2.2. Surgical protocol

Twenty-eight New Zealand rabbits, weighing about 400 g each, were used for the experimental procedure. Fourteen rabbits were operated at the right tibia under general anaesthesia [22], and a cortical defect of 8 × 8 mm was carried out in the front wall, 2 cm below

the joint of knee. A round burr mounted on a low-speed handpiece, under saline irrigation, was used.

Other fourteen rabbits were operated at the right angle of the mandible, that was reached through a small cutaneous incision [29] (Fig. 1). Three holes were carried out in the lower wall; two smaller, about 2×2 mm, served to place two gutta percha points, as radiological landmarks; a third cavity of about 8×8 mm was made between the marks. Before drilling, periosteum was removed, exposing a large portion of bone, both in tibia and mandible. The cortical plate was drilled until the medullary cavity.

2.2.1. Tibia experiments

To evaluate the healing of surgical defects in tibia 14 animals were treated and the experimental protocol was as follows:

In three rabbits POP membranes were implanted and taken after one month.

In three rabbits POP membranes were implanted and taken after two months.

In two rabbits POP trimethoprim-enriched membranes were implanted and taken after one month.

In two rabbits POP naproxen-enriched membranes were implanted and taken after one month.

In two rabbits a PTFE membrane was placed on the surgical bone defect and one animal was sacrificed after one month, and the second after two months.

Two rabbits with untreated defect were used as controls.

2.2.2. Mandible experiments

To evaluate the surgical defect in mandible, fourteen animals were treated and the experimental protocol was as follows:

In two rabbits the defect was filled with POP succinylsulphathiazole (SST) enriched microspheres added to granular hydroxyapatite (HA), in a weight ratio of 10:90 and covered with POP membranes.

In two rabbits the defects were filled with SST-enriched microspheres mixed with granular HA in a weight ratio of 10:90 while no membrane was used to cover the defect.

In two rabbits the defect was filled with POP microspheres enriched with SST, while no membrane was used to cover the defect.

In two rabbits the defect was filled with POP microspheres enriched with SST and covered with POP membrane.

In two rabbits the defect was covered with POP membrane.

In two rabbits the defect was covered with PTFE membrane.

Two rabbits with untreated defects were used as controls. All of the animals operated in the mandible were sacrificed after one month.

Membranes, when used, were placed carefully on the bone defect, until a distance of at least 1 cm from its border, on the surrounding bone, in order to prevent the collapse of the soft tissues, while microspheres, when utilised, were inserted in order to fill completely the defect.

The soft tissue was sutured with 2/0 catgut, and the skin with 3/0 silk, and ampicilline was given orally to each animal for one week after operation, while ampicilline powder was placed in the wound. After one and two months, the animals were sacrificed with an intravenous injection of air, bones containing the defects were taken and fixed in 80% ethanol with 0.5% acetic acid. The samples were embedded in resin (Technovit 7200, Kulzer), subsequently cut and ground until a thickness of about 30 micron. After staining with both acid and basic fuchsin and methylene blue, the samples were examined in light microscopy.

3. Results

3.1. Membranes and microspheres degradation and release properties

Table I reports polyphosphazenes properties found in previous studies of our laboratories, that are relevant to an oral surgical application [25–28, 30]. The reported

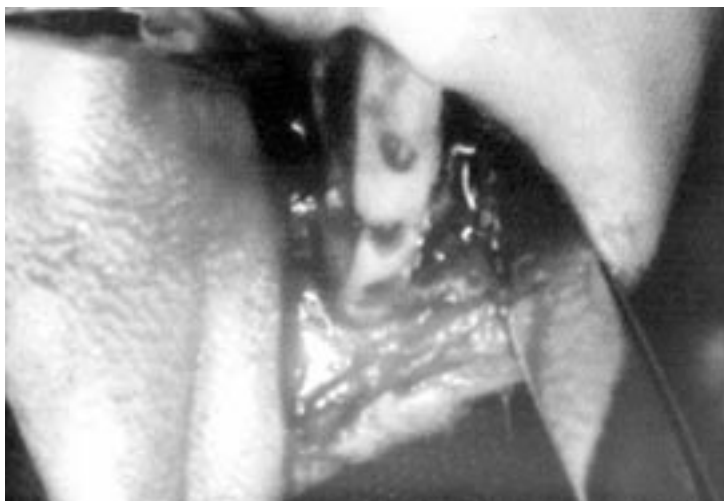

Figure 1 A POP membrane is placed for covering a surgical breach in rabbit mandible.

TABLE I Relevant properties of membranes and microspheres related to their use in periodontal diseases and implant surgery. These data were obtained in our laboratory [25–30]

Membranes degradation after two months (%):	
prepared from polymer I	25
prepared from polymer II	47
Drug released from loaded membranes after 10 days (%):	
Succinylsulphathiazole	75
Trimethoprim	90
Naproxen	10
Time in which a therapeutically useful concentration of drug is maintained in mandible following release from matrices loaded with:	
Trimethoprim	48 h
Succinylsulphothiazole	72 h
Drug released from microspheres after 20 days (%):	
Succinylsulphothiazole	35
Naproxen	48

data are in favor of the use of POP membranes and microspheres in the guided tissue regeneration in surgical treatment of periodontal disease and in implant dentistry. From the table we can in fact understand that membranes, useful in implant surgery to separate tissue of different properties and growing rate, can be successfully prepared with both polymer I or II, since they are degraded slowly in buffer conditions (see table). In particular those prepared with polymer I loose about 25% of weight in two months still maintaining their shape and the functionality. It is worth of note also the fact that the polymer I membranes are soft enough to be properly placed in a surgical area and adapted to its shape.

It must be remembered that this polymer was also successfully employed in our laboratory to prepare tubes for nerve regeneration channelling [30, 31]. Furthermore the membranes were also be successfully loaded with different drugs, as those possessing antibacterial or antiinflammatory activity, without impairing their structural properties. In rats the entrapped drugs were slowly released at a rate that assured the therapeutic level into the surrounding tissue for several days [27].

Microspheres can in turn be prepared with polymer II and loaded with drugs. From these matrices the release kinetic is slower of the one observed in matrices. The microspheres can be prepared at a diameter of 60–80 μm , a value which is small enough to yield a water suspension suitable to be injected into the tissue with an hypodermic syringe provided that a needle of proper size is employed [28].

3.2. Histological results

Experimentations were carried out using both empty or drug loaded membranes and microspheres in order to verify their effect on tissue healing. Drug loaded matrices were also employed to investigate the tissue behavior when a model drug is released *in situ* during the healing process. The study was accomplished in two types of bone tissues: tibia and mandible.

Microspheres were used to fill the bone defect in addition to hydroxyapatite (HA), a material usually employed as alloplastic bone substitute. In the experimentation drug loaded microspheres (10%) were added

to hydroxyapatite (90%) to verify whether the released drug could negatively interfere with the bone regeneration while playing its useful antibacterial or anti-inflammatory action. The results, as reported below, indicate that not only no negative effect takes place, but on the contrary an increasing healing was observed in some case.

The results obtained are reported below, according to the site of implants.

3.2.1. Tibia

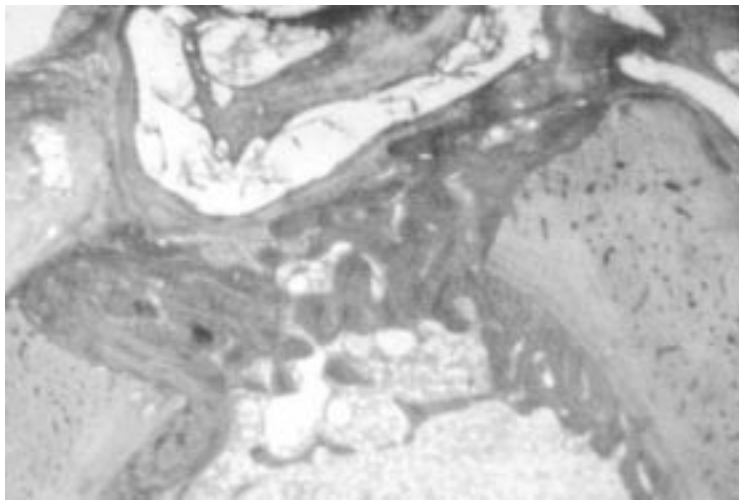
All tibiae were found uneventfully healed. In particular in the experimental defects covered with POP membranes, after one month, bridges of newly-formed bone were present, closing the wound as it is shown in Fig. 2a. At higher magnification (Fig. 2b) this repairing bridge, composed of osteoid tissue, showed sprightly osteoblastic activity, with some newly-formed bone lacunae. The POP membranes were still visible, swelled and folded, with initial resorption. This behavior was probably related to hydrolysis, since no multinucleated phagocytic cells were found, as it was instead reported to occur with polylactic acid [11]. After two months, the defect was almost completely filled by repairing bone (Fig. 2c).

On the contrary, in the control animals and in those treated with PTFE membrane, the bone defect was found to be still opened, even after two months, with a scarce amount of newly-formed bone as shown in Fig. 2d. Apparently the non-resorbable membranes did not facilitate the healing of the bone wound, even if they were well-tolerated, as demonstrated by the fact that no sign of inflammation was detected around them.

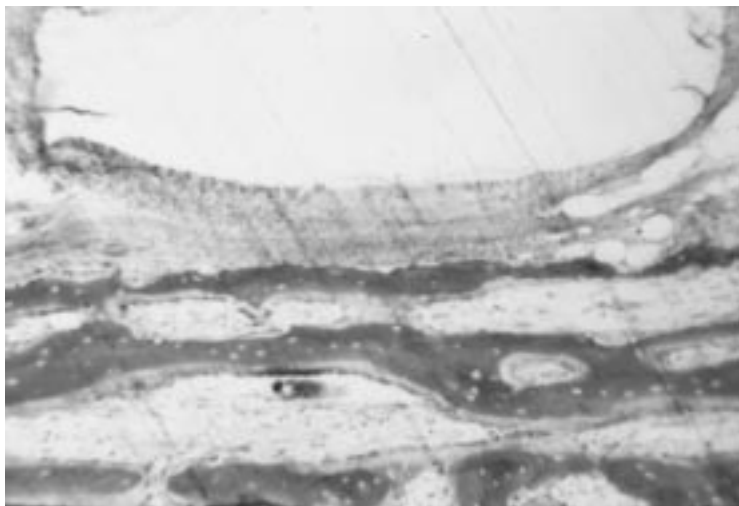
Furthermore, it is also worth to report that the results obtained with pure POP membranes and with the drug-enriched POP ones were practically identical, demonstrating that drug release is not harmful for the healing process. In all of the treated animals, repairing was observed after one month, with the defect filled by newly-formed bone tissue. The percentage of the defect closure was evaluated around 50%. On the other hand, in controls and animals with PTFE membrane, the estimated average of new bone repairing the defect was only 20% or even less.

After two months, the POP membrane showed advanced resorption, appearing as granules, as it is seen in Fig. 2c. The surgical wound was almost completely filled by bone. Only a finding, not significant with regard to healing osteoinduction, was observed in one sample in the muscular and connective tissue over the site of membrane: rare multinucleated cells with many osteoblasts were observed in the proximity of membrane remnants.

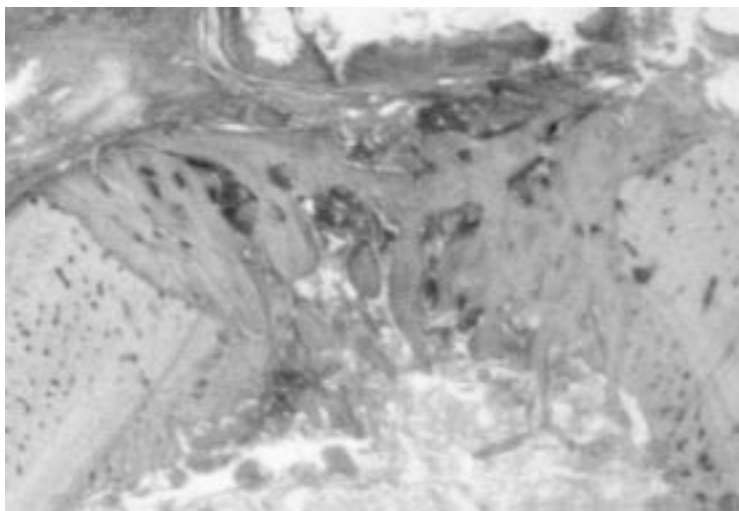
In the control animals, on the contrary of what observed in the treated ones, soft connective fibrous tissue was found, infolded into the surgical defect, showing a scanty amount of repairing bone tissue (evaluated in 30%). This picture was also found in rabbits treated with PTFE membrane.



(a)

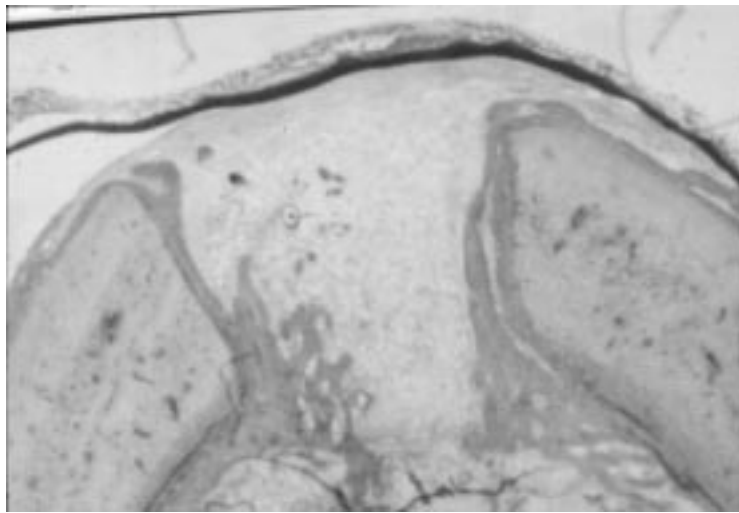


(b)



(c)

Figure 2 Experimental breach in rabbit tibia: (a) With POP membrane after 1 month newly-formed bone is closing the defect. The membrane is still visible, looking folded upward, with signs of initial resorption. The membrane is unstained, as it does not absorb histologic dyes (basic fuchsin and methylene blue, original magnification 20×); (b) Detail of (a) at higher magnification. Osteoblasts with repairing bone are visible under the POP membrane (Toluidine blue and basic fuchsin, o.m. 120×); (c) After 2 months the defect was covered with a POP membrane, which seems to be completely resorbed. A large amount of repairing bone is visible. The healing process appears to be in an advanced phase, with the bone defect mostly filled by newly-formed bone. This repairing tissue has an aspect like to a bone callus. (Basic fuchsin and methylene blue, o.m. 20×); (d) With PTFE membrane after one month the defect is still opened, and only a scarce amount of newly-formed bone is detectable. The membrane is clearly visible (basic fuchsin and methylene blue, o.m. 6×).



(d)

Figure 2 (Continued)

3.2.2. Mandible

The soft tissues of all samples healed uneventfully. At the microscopic examination, POP microspheres were mostly resorbed with the appearance of vacuoles. Microspheres alone did not seem to improve the healing, since the defects, when completely filled with particles, remained still opened, with a percentage of newly-formed bone in the breach valuable in 50% or less (Figs 3a–c), while in the rabbits treated with both POP microspheres and membranes, variable amounts of newly-formed bone were found (Figs 4a–e).

On the other hand, defects covered with PTFE membrane were still opened, with a scanty amount of repairing bone (Fig. 5a), and the two control rabbits showed an advanced closure of the mandibular defect by newly-formed bone (Fig. 5b). No bone was found in proximity of the gutta percha landmarks.

It must be underlined that no apparent inflammatory response was detected, and that bone was often in tight proximity of the grafted particles that were mostly resorbed, but still visible (Figs 3a, 4a, and 4c). Furthermore, the membranes were almost completely resorbed after one month, without any presence of macrophages.

Newly formed bone was found originating from the walls of the defect in treated mandibles, and in some instances it was in close contact with both POP and HA granules (Figs 5c–5f). It is important to note that no relationship was found between the degree of bone regeneration and the addition of drugs in POP microspheres or membranes, since they seem to evoke the same tissue reaction as the empty ones.

Regarding HA tissue reaction, macrophages, mostly mononucleated, entrapping small particles of HA were also found (Fig. 5d), and at very high magnification a close proximity between osteoblasts and osteoclasts was found, suggesting bone remodeling (Fig. 5e). In spite of the phagocytic activity affecting HA (but not POP microspheres), HA showed a limited degree of resorption, while POP granules were almost totally resorbed after one month (Fig. 5f).

In any case, the worst results were observed in the

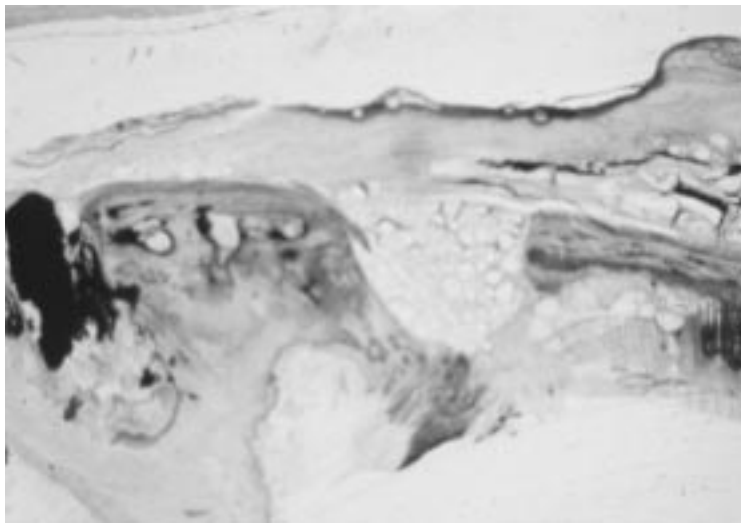
defects covered with PTFE membranes, since a very scarce repairing bone was present (Fig. 5a), although in general a comparison with untreated animals indicated that, under the same experimental protocol, the use of membranes and/or grafting, that is mandatory in the tibia (see above), may be unnecessary for the healing of such mandibular defects (Fig. 5b).

Finally, the trial indicates also that with a different less biocompatible material, as the gutta percha used for the landmarks, repairing bone was never in tight contact with gutta, that was always surrounded by soft tissue, without signs of inflammation (Figs 4a, 5b).

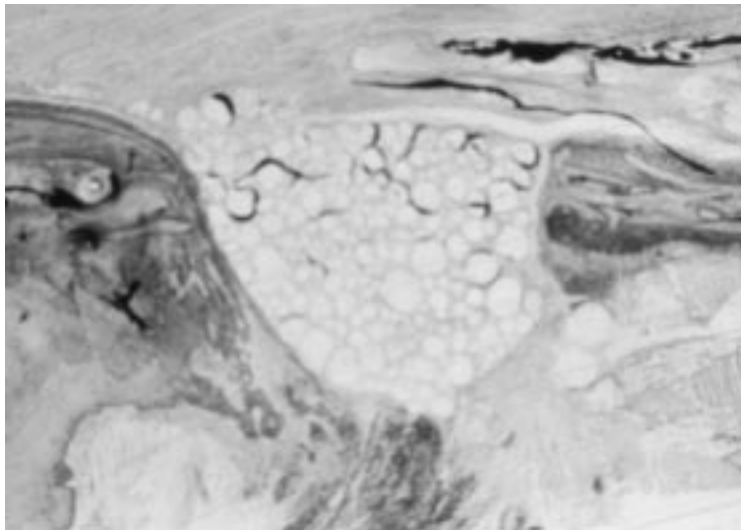
4. Discussion and conclusions

A clear positive influence of covering the defect with plain or drug loaded POP membrane was demonstrated in tibia whereas in mandible spontaneous closure with new bone formation could also be seen in control animals. This demonstrates how critical could be the choice of the experimental model to verify the success or the need of a biomaterial in the healing process. However, the bone of rabbit, especially the long ones, are considered to be a valid experimental model for easy of surgical access [32]. The defects in tibiae appeared to be more sensitive to the treatment received in this study. Indeed, these resorbable barriers proved to be very effective in promoting the healing in tibiae, compared with PTFE membranes and untreated animals.

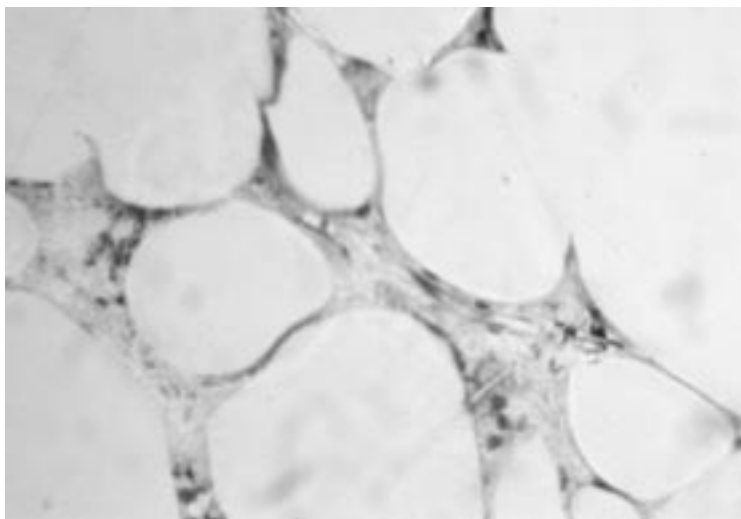
Regarding the use of microspheres as a bone substitute, it was found that POP microspheres alone do not have negative action on the bone itself, because the healing process in mandible occurred in the same way of the control animals. This is a welcome result, since it is a prerequisite for any further use of such materials as drug carriers. The addition of POP microspheres, either alone or drug-enriched, to HA granules, allowed to detect the different pattern of resorption of these materials. It was thus found that POP microspheres resorb quickly, without intervention of macrophages, that instead seemed to play a role in the clearance of HA.



(a)

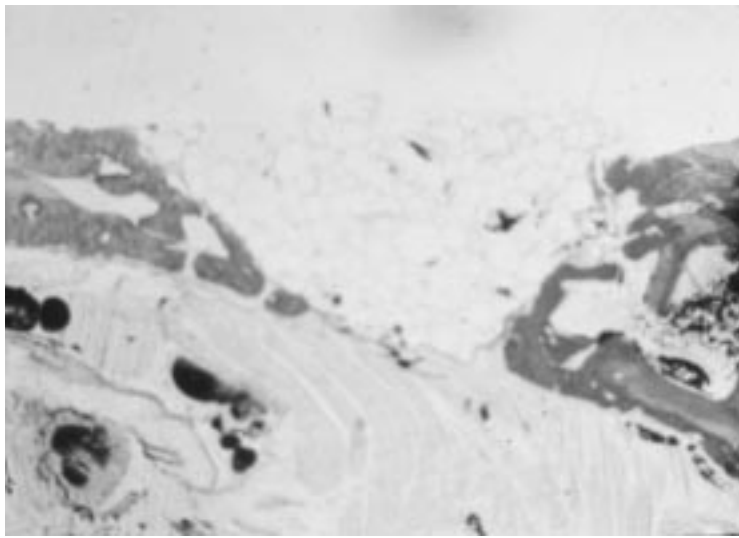


(b)

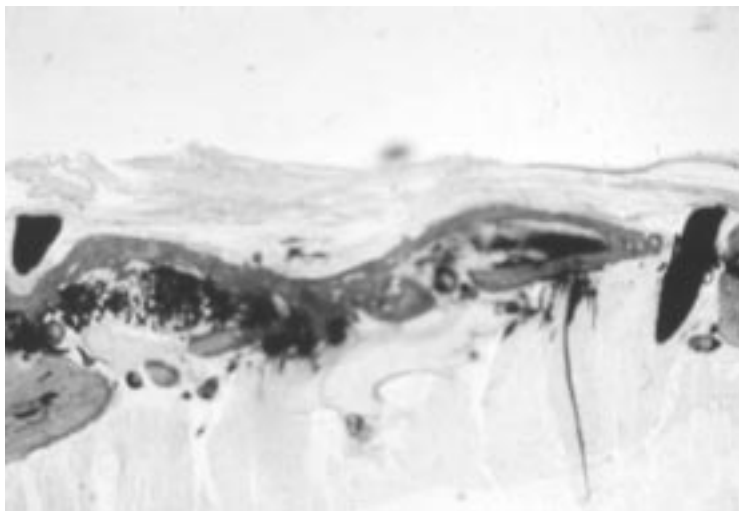


(c)

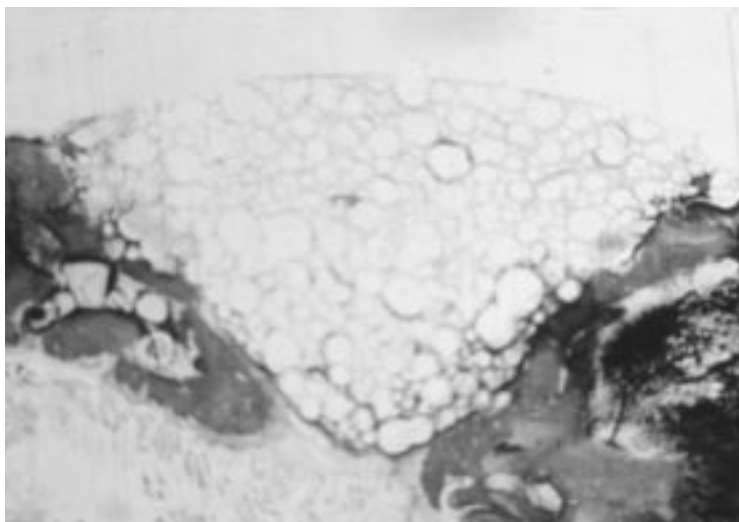
Figure 3 Defect in rabbit mandible filled with POP microspheres without membrane. (a) The particles are partially resorbed after one month, and are still visible as vacuoles. The surgical breach is still detectable, with a near gutta percha landmark. Some repairing bone is present (basic fuchsin and methylene blue, o.m. 15 \times) (b) Higher magnification of (a) The aspect of the granules suggests a dissolution due to hydrolysis, as no macrophages or other inflammatory cells are visible. A layer of newly-formed bone is visible in the deepest part of the defect (acid fuchsin and methylene blue, o.m. 30 \times) (c) Detail of (b). Mesenchymal cells and vessels in the space among grafted microspheres, with no macrophages or inflammatory cells (acid fuchsin and methylene blue, o.m. 120 \times).



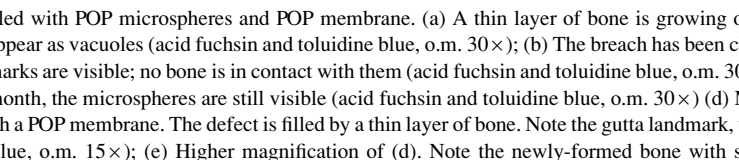
(a)



(b)



(c)

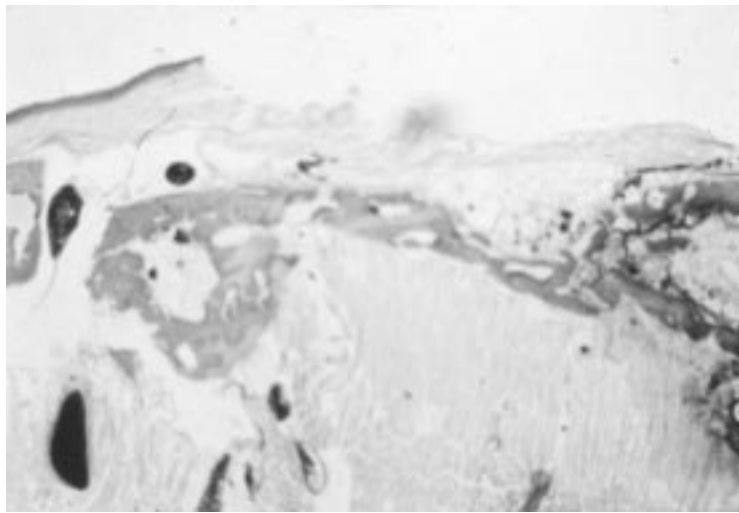


(d)

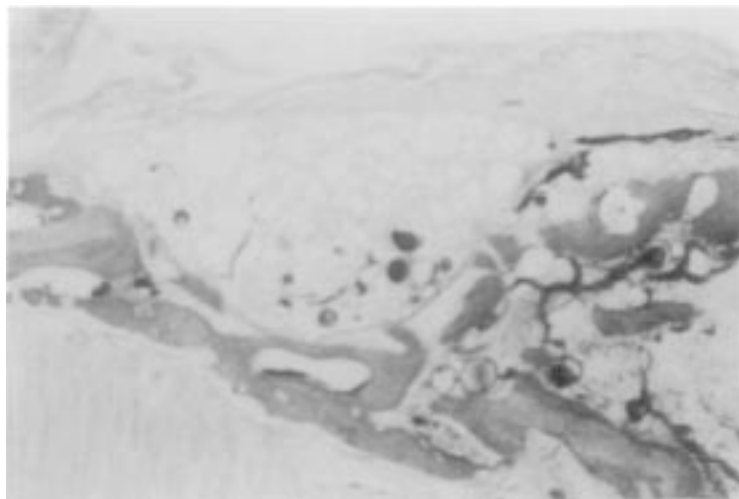


(e)

Figure 4 Mandible defect filled with POP microspheres and POP membrane. (a) A thin layer of bone is growing on the surgical breach. Partially resorbed POP microspheres appear as vacuoles (acid fuchsin and toluidine blue, o.m. 30×); (b) The breach has been closed by a thin layer of compact bone. Two gutta percha landmarks are visible; no bone is in contact with them (acid fuchsin and toluidine blue, o.m. 30×); (c) Partial closure of defect by lamellar bone. After one month, the microspheres are still visible (acid fuchsin and toluidine blue, o.m. 30×) (d) Mandible defect filled with POP microspheres and covered with a POP membrane. The defect is filled by a thin layer of bone. Note the gutta landmark, with no repairing bone around it (acid fuchsin and toluidine blue, o.m. 15×); (e) Higher magnification of (d). Note the newly-formed bone with some lacunae, and the partially resorbed particles. Bone is in proximity of the POP microspheres (acid fuchsin and toluidine blue, o.m. 30×).



(d)



(e)

Figure 4 (Continued)

In all the experiments the biocompatibility of POP appeared excellent, as no sign of inflammation was detected, and the resorption occurred without any phagocytosis. These findings suggest a hydrolytic resorption of POP polymer, that takes place without activation of the cellular immune system. Such results seem to be of importance, considering that other resorbable polymers, such as PGA, were found to evoke immune cellular response [33]. In spite of this, PGA was considered suitable for clinical use, because it showed favorable effects in treating bone dehiscences around titanium implants in sheeps [14].

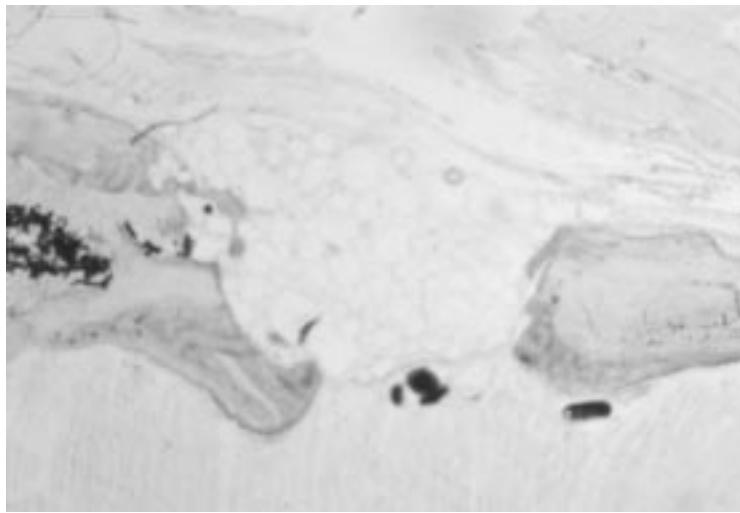
In conclusion, POP polymers, either pure or drug-loaded, seem to be an highly biocompatible resorbable material to make biological barriers for surgery. In addition the polymer possesses the useful property to ensure, if needed, a time-lasting release of drugs that can be easily entrapped in its chemical structure, without hampering the polymer biocompatibility and properties.

On this basis the use of POP microspheres mixed with HA particles to fill bone defects, may be considered very useful for the slow resorption of HA, that allows a longer time for the graft to stay in place, preventing soft tissue

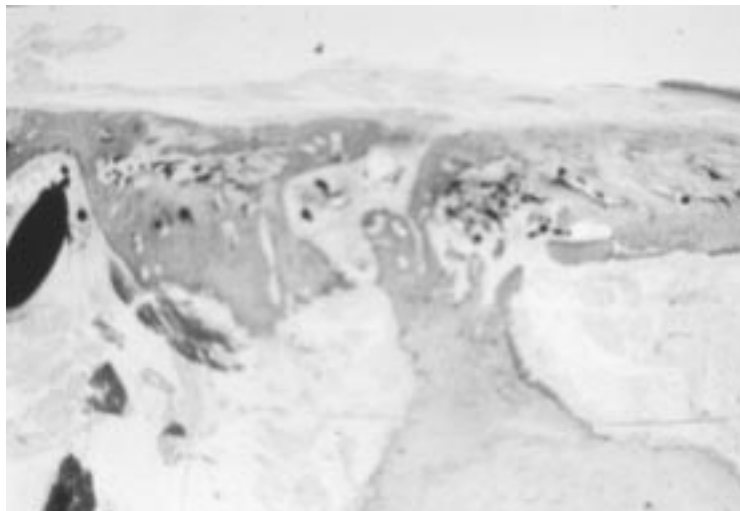
infolding. With regard to this, a HA/POP ratio of 90% appeared suitable for bone reparative surgery, and guided tissue regeneration in dentistry.

Further investigations are necessary to establish the use of this polymer in oral surgery, in particular to determine the proper thickness and composition of POP membranes, in order to get the best resorption rate. A retention time of one-two month for a barrier, the time of duration of the POP membranes used in this study, may probably be considered a too short one. Better results were in fact reported [34] if the barrier stays in place for three months or more. In this instance, the chemical properties of POP polymers indicate that this need may be satisfied by a proper choose of the components during the synthesis [25, 26].

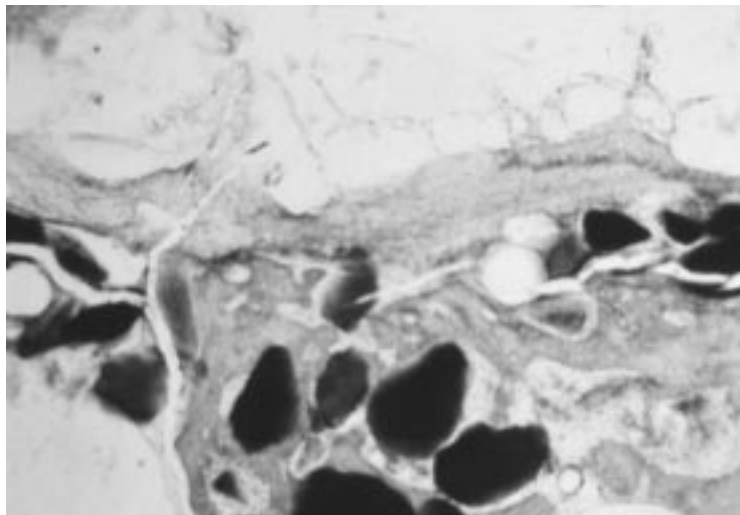
As a final consideration, a further interesting improvement of the technique might be the entrapment of bone and tissue growth-factors into these polymers, to be locally released to possibly reduce the healing time. This last possibility seems feasible since a recent research from our laboratory carried out with POP entrapped calcitonin demonstrated the possibility to release polypeptides from POP matrices [35].



(a)

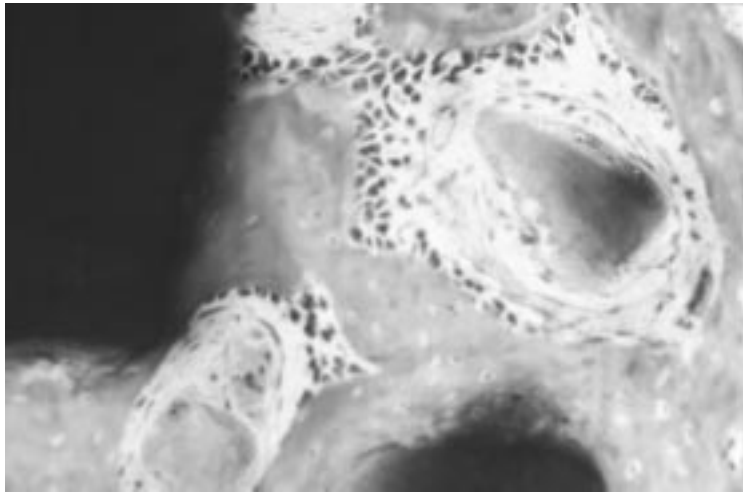


(b)

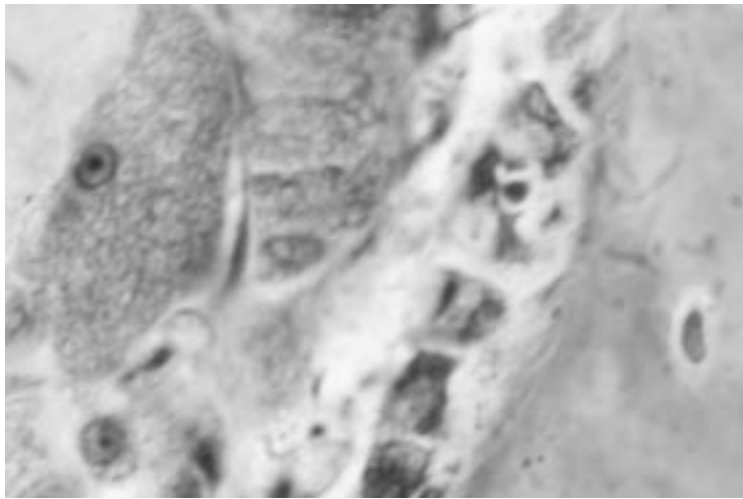


(c)

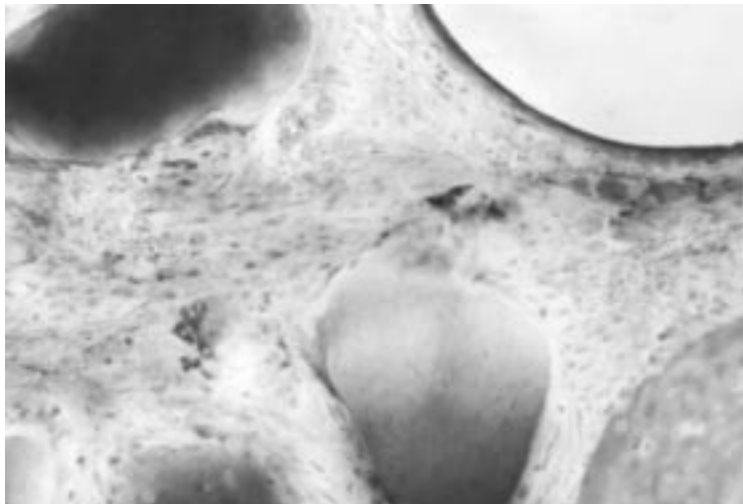
Figure 5 Mandible defect covered with PTFE membrane; control rabbit; animal with inserted HA and POP particles. (a) Surgical defect in rabbit mandible, covered with a PTFE membrane. Very low quantity of repairing bone is detectable (acid fuchsin and toluidine blue, o.m. 30 \times); (b) Control rabbit, with unfilled and uncovered mandible defect, after one month. Almost complete closure of the breach by newly formed lamellar bone with lacunae. The repairing bone near the gutta landmark may also be observed; however, no bone is in contact with gutta (acid fuchsin & toluidine blue, o.m. 30 \times); (c) Newly-formed bone surrounding HA and POP particles. The POP membrane is still recognizable (acid fuchsin and toluidine blue, o.m. 120 \times); (d) Detail of (c) At higher magnification, showing some HA particles surrounded by new bone, while others are resorbing and surrounded by mononucleated macrophages. Intense osteoblastic activity is following the resorption of HA granules (acid fuchsin and toluidine blue, o.m. 200 \times); (e) At a very high magnification of (c), a close proximity between osteoblasts and osteoclasts is visible (acid fuchsin and toluidine blue, o.m. 1200 \times); (f) HA and POP particles with newly-forming bone; POP is almost totally resorbed, while HA retains its structure, showing some resorption (acid fuchsin and toluidine blue, o.m. 200 \times).



(d)



(e)



(f)

Figure 5 (Continued)

References

1. S. NYMAN, J. LINDHE, T. KARRING and H. RYLANDER, *J. Cl. Periodontol.* **9** (1982) 290.
2. P. CORTELLINI, G. PINI PRATO, C. BALDI and C. CLAUSER, *Int. J. Period. Restor. Dent.* **2** (1990) 137.
3. D. BUSER, U. BRAGGER, N. P. LANG and S. NYMAN, *Cl. Oral Impl. Res.* **1** (1990) 22.
4. W. BECKER, C. DAHLIN, E. BECKER, U. LEKHOLM, D. VAN STEENBERGHE, K. HIGUCHI and C. KULTJE, *Int. J. Oral Maxillofac. Implants* **1** (1994) 31.
5. S. AMAR, K. M. CHUNG, S. H. NAM, S. KARATZAS, F. MYOKAI and T. E. VAN DYKE, *J. Periodontal Res.* **32**(1) Pt2 (1997) 148.
6. W. BECKER, B. BECKER, L. BERG, J. PRICHARD, R. CAFFESSE and E. ROSEMBERG, *Int. J. Periodontics Rest. Dentistry* **3** (1988) 9.
7. R. SCHALLHORN and P. MCCLAIN, *ibid.* **4** (1988) 9.
8. M. TANNER, C. W. SOLT and S. VUDDHAKANOK, *J. Periodont.* **59** (1987) 524.
9. A. H. GAGER and A. J. SHULTZ, *ibid.* **62** (1991) 276.
10. S. VUDDHAKANOK, C. W. SOLT and J. C. MITCHELL, *ibid.* **64** (1993) 202.
11. J. GOTTLAW, D. LUNDGREN, S. NYMAN, L. LAURELL and H. RYLANDER, *J. Dent. Res.* **71**(spec. issue) (1992) 297 (Abstr. 1535).
12. J. GOTTLAW, *J. Periodontol.* **64**(11) (1993) 1157.
13. D. LUNDGREN, L. SENNERBY, H. FALK, B. FRIBERG and S. NYMAN, *Cl. Oral Impl. Res.* **5** (1994) 177.
14. J. MUHONEN, R. SUURONEN, V. J. OIKARINEN, E. SARKIALA and P. HAPPONEN, *Journal of Material Science: Materials in Medicine* **5** (1994) 40.
15. T. S. LEENSTRA, J. C. MALTHA and A. M. KUIJPERS-JAGTMAN, *ibid.* **6** (1995) 445.
16. E. A. BAKKUM, J. B. TRIMBOS, R. A. J. DALMEIJER and C. A. VAN BLITTERSWIJK, *ibid.* **6** (1995) 41.
17. G. ZUCHELLI, M. DE SANCTIS and C. CLAUSER, *J. Periodontol.* **68**(10) (1997) 996.
18. R. A. YUKNA and C. N. YUKNA, *J. Periodontal Res.* **32**(8) (1997) 627.
19. A. T. SHIEH, H. L. WANG, R. O'NEAL, G. N. GLICKMAN and R. L. MACNEIL, *J. Periodontol.* **68**(8) (1997) 770.
20. T. A. SCOTT, H. J. TOWLE, D. A. ASSAD and B. K. NICOLL, *ibid.* **68**(7) (1997) 679.
21. P. HYDER, D. QUTEISH, G. SINGH and A. E. DOLBY, *J. Dent. Res.* **68** (spec. issue) (1989) 932, (Abstr. 528).
22. M. AABOE, E.M. PINHOLT, E. HJORTING-HANSEN, E. SOLHEIM and F. PRAETORIUS. *Cl. Oral Impl. Res.* **4** (1993) 172.
23. N. FLEISHER, H. DE VAAL and A. BLOOM, *Int. J. Period. Restor. Dent.* **2** (1988) 45.
24. E. FONTANA, P. TRISI and A. PIATTELLI, *J. Periodontol.* **65** (1994) 658.
25. P. CALICETI, S. LORA, F. MARSILIO, A. GUIOTTO and F. M. VERONESE, *Il farmaco* **49** (1994) 69.
26. P. CALICETI, S. LORA, F. MARSILIO and F. M. VERONESE, *ibid.* **50** (1995) 867.
27. A. CONFORTI, S. BERTANI, S. LUSSIGNOLI, L. GRIGOLINI, M. TERZI, S. LORA, P. CALICETI, F. MARSILIO and F. M. VERONESE, *J. Pharm. Pharmacol.* **48** (1996) 468.
28. F. M. VERONESE, F. MARSILIO, P. CALICETI, P. DE FILIPPIS, P. GIUNCHEDI and S. LORA, **52** (1998) 227-237.
29. C. DAHLIN, J. LINDE, J. GOTTLAW and S. NYMAN, *Plastic Recon. Surg.* **81** (1988) 672.
30. N. N. ALDINI, M. FINI, M. ROCCA, L. MARTINI, R. GIARDINO, P. CALICETI, F. M. VERONESE, S. LORA and M. C. MALTARELLO, *J. Bioactive and Compatible Polymers* **12** (1997) 3.
31. F. LONGONE, S. LORA, F. M. VERONESE, P. CALICETI, P. P. PARNIGOTTO, F. VALENTI and G. PALMA, *Biomaterials* **16** (1995) 347.
32. L. KRYSANDER, S. HELLEM, A. BERGGREN and B. KLINGE, *Clin. Oral Impl. Res.* **8** (1997) 506.
33. S. SANTAVIRTA, Y. T. KONTTINEN, S. TOMOYUKI, M. GRONBLAD, E. PARTIO, P. KEMPPINEN and P. ROKKANEN, **72-B** (1990) 597.
34. U. LEKHOLM, W. BECKER, C. DAHLIN, B. BECKER, K. DONATH and E. MORRISON, *Cl. Oral Impl. Res.* **4** (1993) 121.
35. P. CALICETI, N. N. ALDINI, M. FINI, M. ROCCA, S. GNUDI, S. LORA, G. GIAVARESI, C. MONFARDINI, R. GIARDINO and F. M. VERONESE, *Il Farmaco*, **52** (1997) 697.

Received 27 January
and accepted 11 August 1999